Quantification of Femoral Neck Exposure Through a Minimally Invasive Smith-Petersen Approach

James A. Blair, MD CPT MC USA,† Daniel J. Stinner, MD CPT MC USA,‡ Jess M. Kirby, MD MAJ MC USA,§ Tad L. Gerlinger, MD LTC(P) MC USA,† Joseph R. Hsu, MD MAJ(P) MC USA,‡ and the Skeletal Trauma Research Consortium (STReC)

Objectives: To quantify the area of osseous exposure and identify six anatomic landmarks using a direct anterior approach to the hip.

Methods: Ten fresh frozen hemipelves were dissected using a minimally invasive Smith Petersen approach. Upon completion of the exposure, a calibrated digital image was taken from the surgeon's perspective. Identification of six osseous landmarks (anterior superior acetabulum, anterior inferior acetabulum, greater trochanter, lesser trochanter, anterior inferior iliac spine, and vastus ridge) was attempted either by direct visualization or palpation with a tonsil clamp. These landmarks exceed the border for any intracapsular hip fracture. The digital images were then analyzed using a computer software program, *ImageJ* (National Institutes of Health, Bethesda, MD), to calculate the square area of proximal femur exposed.

Results: The average square area of proximal femur exposed was 20.31 cm^2 (standard deviation: 3.09, range: 15.16 24.18). The area exposed correlated with the original height of the cadaver (r 0.69, $P < 0.05$). With the numbers available, there was no correlation between exposure and weight (P 0.71) or body mass index (P 0.87). In all 10 cadaver specimens, the 6 osseous landmarks were easily identified, 5 by direct visualization and 1 by palpation (lesser trochanter, deep portion) because of incomplete visualization.

Conclusions: The minimally invasive Smith Petersen approach to the hip allows for a wide exposure of the femoral neck averaging 20.31 cm^2 and identification of six bony critical landmarks of the hip. It may be used for open reduction of subcapital, mid cervical, and basicervical femoral neck fractures.

Key Words: Smith Petersen, surgical exposure, anterior hip approach, femoral neck fracture

(*J Orthop Trauma* 2010;24:355 358)

INTRODUCTION

Adequate visualization is paramount when attempting open reduction of femoral neck fractures because it provides a view of the fracture pattern and its subsequent reduction. The Watson-Jones anterolateral approach has been traditionally used for open reduction and internal fixation of displaced femoral neck fractures.[1–7] However, it involves dissection between the gluteus medius and the tensor fascia latae, which is an intermuscular plane, not an internervous plane, and thus involves risk of damage to the superior gluteal nerve.[1,8] Many illustrations and descriptions of the anterolateral approach are actually extensions of the direct lateral approach (i.e., Hardinge approach).[9,10] Alternatively, the direct anterior minimally invasive Smith-Petersen approach has also been described to reduce displaced femoral neck fractures.[11–18] It is a true internervous plane between the muscles innervated by the femoral nerve and the superior gluteal nerve.[19,20] The superficial interval is between the sartorius and tensor fascia latae, whereas the deep interval is between the rectus femoris and the gluteus medius. Using this interval decreases the risk of muscle denervation. A technique for the reduction of displaced femoral neck fractures using the Smith-Petersen approach to the hip has recently been described.[21] The purpose of this study is to quantify the amount of osseous exposure while identifying multiple high-yield osseous landmarks within the exposure using the minimally invasive Smith-Petersen approach to the hip. To our knowledge, quantitative studies of visual exposure of this approach have yet to be described in the literature.

MATERIALS AND METHODS

Ten fresh frozen cadaveric limb specimens (each composed of 1 hemipelvis) were used. None of these specimens had evidence of previous surgery, arthrofibrosis, or trauma to the hip. All procedures were performed by the two senior authors (TLG and JRH). These authors are fellowship-trained in arthroplasty and trauma, respectively. A minimally

Accepted for publication October 16, 2009.

From the *Department of Orthopaedic Surgery, Brooke Army Medical Center, Fort Sam Houston, TX; †Department of Orthopaedics and Rehabilitation, Brooke Army Medical Center, Fort Sam Houston, TX; ‡United States Army Institute of Surgical Research, Brooke Army Medical Center, Fort Sam Houston, TX; and §United States Army Trauma Training Center/ Ryder Trauma Center, Miami, FL.

JRH receives institutional research support from the Geneva Foundation. None of the other authors or the Skeletal Trauma Research Consortium have any financial disclosures to make. None of the authors have received any funding from the National Institutes of Health, Wellcome Trust, or the Howard Hughes Medical Institute.

This study will be presented at the 28th Annual Meeting of the Mid-America Orthopaedic Association on April 22, 2010.

Reprints: James A. Blair, MD CPT MC USA, Department of Orthopaedic Surgery, Brooke Army Medical Center, Fort Sam Houston, 78234 TX (e-mail: james.blair@amedd.army.mil; jamesblairjr@gmail.com).

Copyright © 2010 by Lippincott Williams & Wilkins

Copyright © Lippincott Williams & Wilkins. Unauthorized reproduction of this article is prohibited.

Report Documentation Page

Form Approved
OMB No. 0704-0188

Public reporting burden for the collection of information is estimated to average 1 hour per response, including the time for reviewing instructions, searching existing data sources, gathering and maintaining the data needed, and completing and reviewing the collection of information Send comments regarding this burden estimate or any other aspect of this collection of information, including suggestions for reducing this burden, to Washington Headquarters Services, Directorate for Information Operations and Reports, 1215 Jefferson Davis Highway, Suite 1204, Arlington VA 22202-4302 Respondents should be aware that notwithstanding any other provision of law, no person shall be subject to a penalty for failing to comply with a collection of information if it does not display a currently valid OMB control number

1. REPORT DATE **01 JUN 2010**	2. REPORT TYPE **N/A**	3. DATES COVERED **-**
4. TITLE AND SUBTITLE **Quantification of femoral neck exposure through a minimally invasive Smith-Petersen approach**		5a. CONTRACT NUMBER 5b. GRANT NUMBER 5c. PROGRAM ELEMENT NUMBER
6. AUTHOR(S) **Blair J. A., Stinner D. J., Kirby J. M., Gerlinger T. L., Hsu J. R.,**		5d. PROJECT NUMBER 5e. TASK NUMBER 5f. WORK UNIT NUMBER
7. PERFORMING ORGANIZATION NAME(S) AND ADDRESS(ES) **United States Army Institute of Surgical Research, JBSA Fort Sam Houston, TX**		8. PERFORMING ORGANIZATION REPORT NUMBER
9. SPONSORING/MONITORING AGENCY NAME(S) AND ADDRESS(ES)		10. SPONSOR/MONITOR'S ACRONYM(S) 11. SPONSOR/MONITOR'S REPORT NUMBER(S)
12. DISTRIBUTION/AVAILABILITY STATEMENT **Approved for public release, distribution unlimited**		
13. SUPPLEMENTARY NOTES		
14. ABSTRACT		
15. SUBJECT TERMS		

16. SECURITY CLASSIFICATION OF:			17. LIMITATION OF ABSTRACT	18. NUMBER OF PAGES	19a. NAME OF RESPONSIBLE PERSON
a REPORT **unclassified**	b ABSTRACT **unclassified**	c THIS PAGE **unclassified**	**UU**	**4**	

Standard Form 298 (Rev. 8-98)
Prescribed by ANSI Std Z39-18

invasive Smith-Petersen approach was performed on each specimen in the following manner.

Surgical Procedure

With the specimens in a supine position, a 10 cm incision was drawn on the skin using a metric ruler. The incision began at a point one finger-breadth inferior and one finger-breadth lateral to the anterior superior iliac spine.[15] The incision extended in a distal and slightly lateral direction toward the lateral aspect of the patella. This placed the incision directly over the tensor fascia latae muscle belly, which was palpable in the thinner specimens. The muscular fascia of the tensor fascia latae was incised. Finger dissection developed the plane between the medial limb of the muscular fascia and the muscle belly itself, just lateral to the sartorius. This slightly more lateral superficial dissection limits the direct dissection and subsequent scarring of the lateral femoral cutaneous nerve.

Sharp dissection through the deep fascia of the tensor fascia latae promoted the interval between the gluteus medius and rectus femoris muscles. Incision of this deep fascia revealed the ascending branch of the lateral circumflex femoral artery, which is typically ligated.[22] Some specimens required elevation of the iliopectineus to reveal the anterior hip joint capsule.[23] The indirect head of the rectus femoris was not released.

An H-shaped capsulotomy was then performed. Addition of the limb of the H along the intertrochanteric line is safe for the femoral head blood supply, and it makes the neck exposure easier.[23,24] Retractors were then placed within the joint capsule around the neck. Another retractor was carefully placed over the brim of the acetabulum near the anterior inferior iliac spine. The final retractor was placed on the lateral proximal femur at the vastus ridge. No tendons or muscles were released as part of the approach. The only structures incised were skin, fascia, and capsule.

Specific anatomic landmarks were visibly identified or palpated with a tonsil clamp if not in the window of dissection. These structures included the anterior aspect of the superior acetabulum, the anterior aspect of the inferior acetabulum, the greater trochanter, the lesser trochanter, the anterior inferior iliac spine, and the vastus ridge. After completion of the exposure, four retractors were placed adjacent to the femoral neck, with gentle retraction of the soft tissues. A calibrated digital photograph of the exposed proximal femur was taken from directly above the dissection, which represented the surgeon's perspective. These digital images were analyzed using a computer software program, *ImageJ* (National Institutes of Health, Bethesda, MD).[25] This computer program compared a known distance (i.e., the metric ruler in each image) with the actual number of pixels in the digital photograph. The software used this information to calculate the square area of the proximal femur seen in each exposure. The acetabulum was excluded from the measurements. In all cases, portions of the femoral neck and head that were obscured by retractors were excluded. The soft tissue distal to the capsulotomy was left intact and thus was the distal border of the measurement.

TABLE 1. Specimen Demographics

Average age, years (range)	68.9 (55 92)
Average height, cm (range)	171.6 (157.5 185.4)
Average weight, kg (range)	78.2 (36.1 131.3)
Average body mass index (range)	25.9 (14 42)
Sex	7 male, 3 female
Race	8 white, 1 Hispanic, 1 white/Indian
Operative site	6 right, 4 left

RESULTS

The described approach was successfully accomplished in all specimens. Cadaveric demographic data can be found on Table 1. The average square area of proximal femur exposed was 20.31 cm^2 (standard deviation: 3.09, range: 15.16–24.18). The area exposed correlated with the vertical height of the specimen ($r = 0.69$, $P < 0.05$). With the numbers available, there was no correlation between exposure and weight ($P = 0.71$) or body mass index (BMI) ($P = 0.87$). In all 10 cadaver specimens, the 6 osseous landmarks were easily identified (Table 2). Five of the critical landmarks were directly visible within the field in all specimens (Figs. 1–3). One landmark (lesser trochanter) could not be visualized in its entirety within the field in any specimen (Fig. 4). Only the superior base of the lesser trochanter could be visualized. The remainder of the structure could be easily palpated in all specimens. In addition, there was no statistically significant correlation between square area exposed and sex ($P = 0.46$) or operative side ($P = 0.33$) with the numbers available.

DISCUSSION

An anterior approach to the hip joint was described in 1917 and later detailed in 1949 by the same author, describing a true anterior internervous plane between the sartorius (femoral nerve) and the tensor fascia latae (superior gluteal nerve).[19,20] The gluteus maximus, tensor fascia latae, and abductor mechanism are left intact, and a true internervous plane is used,[14] as opposed to an anterolateral approach, which

TABLE 2. Specimen Measurements

Cadaver No.	Anatomic Landmarks Identified (n/6)	Square Area Exposed (cm^2)
1	6	23.52
2	6	16.71
3	6	17.82
4	6	20.08
5	6	18.81
6	6	22.84
7	6	21.45
8	6	15.16
9	6	24.18
10	6	22.55

Six anatomic landmarks identified were anterior-superior acetabulum, anterior-inferior acetabulum, greater trochanter, lesser trochanter, anterior inferior iliac spine, and vastus ridge.

© 2010 Lippincott Williams & Wilkins

Copyright © Lippincott Williams & Wilkins. Unauthorized reproduction of this article is prohibited.

FIGURE 1. Anterior inferior iliac spine.

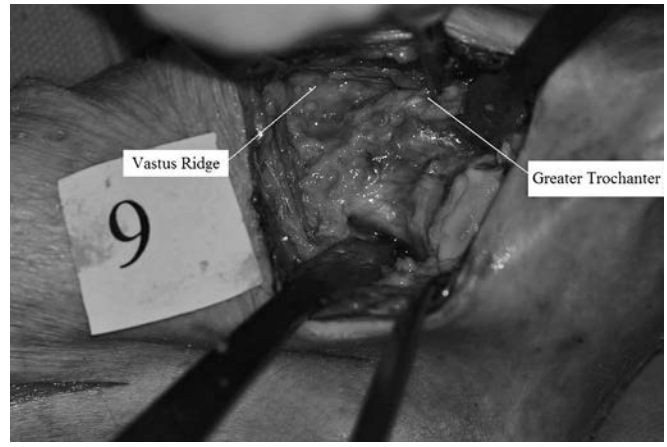

FIGURE 3. Vastus ridge and greater trochanter.

uses an intermuscular plane and thus places the superior gluteal nerve at risk. The direct anterior approach was initially used for hip arthroplasty but recently has gained popularity for open reduction of femoral neck and femoral head fractures.[11,21] The purpose of this study was to quantify the amount of proximal femur exposed while identifying various high-yield osseous landmarks within the dissection using the minimally invasive Smith-Petersen approach to the hip.

Although we do not have sufficient numbers to draw a solid conclusion with respect to body habitus, the number of specimens with a BMI greater than 30 (5/10 specimens) had similar areas exposed when compared with the specimens with a BMI less than 30 (5/10 specimens).

A number of authors have alluded to the excellent visualization of the proximal femur and acetabulum gained by the Smith-Petersen approach, although none have attempted to quantify it.[11–15,21,26] We showed that the average square area of proximal femur exposed was 20.31 cm^2 (standard deviation: 3.09, range: 15.16–24.18). Proponents of the anterolateral or direct lateral approach for femoral neck fractures cite the inability to expose basicervical fractures through an anterior approach.[27] The landmarks identified in this study exceed the borders of any femoral neck fracture. The medial extent of our exposure was limited only by the acetabulum. We had complete proximal and lateral exposure of the anterior surface of the greater trochanter and vastus ridge (Fig. 3). Our inferior limit exposed most of the lesser trochanter (Fig. 4). Further exposure in this direction would not be clinically practical because it could place the femoral head blood supply at risk.[24]

Although this study uses advanced digital imaging software, it is limited by the fact that a two-dimensional image is attempting to represent a three-dimensional surface. The images were taken from the perspective of the surgeon's view, which, in all instances, was directly above and perpendicular to our exposure. Although this surgeon's view photograph may be a weakness of the study, we believe that it may actually underestimate the surface area because manipulation of the retractors may provide even more osseous exposure. In addition, the relatively small number of cadavers available was a limitation.



FIGURE 2. Anterior-superior acetabulum and anterior-inferior acetabulum.

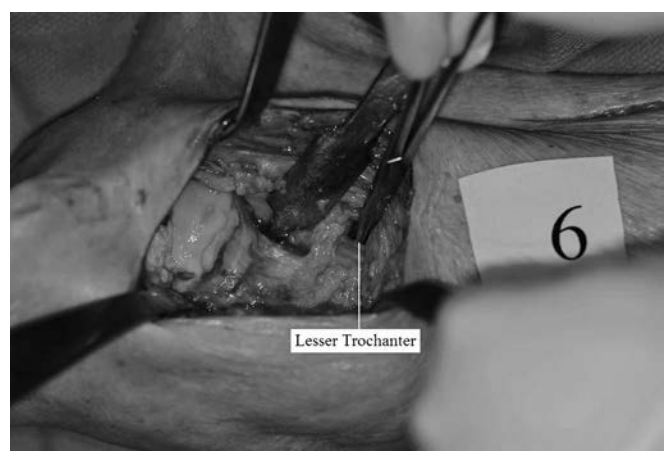

FIGURE 4. Lesser trochanter. Only superior base of lesser trochanter could be visualized. Remainder of structure could be easily palpated.

© 2010 Lippincott Williams & Wilkins

Copyright © Lippincott Williams & Wilkins. Unauthorized reproduction of this article is prohibited.

This exposure affords the surgeon the ability to visualize the femoral neck and head while using a very safe approach through an internervous plane. Release of tendons and muscles are not necessary.

In conclusion, the minimally invasive Smith-Petersen approach to the hip allows for a wide exposure of the femoral neck averaging 20.31 cm^2 and identification of six bony critical landmarks of the hip. Because these bony landmarks exceed the borders of any femoral neck fracture, we believe that this approach should be strongly considered when contemplating open reduction and internal fixation of displaced femoral neck fractures.

REFERENCES

1. Watson-Jones R. Fractures of the neck of the femur. *Br J Surg*. 1936;23: 787 808.
2. Swiontkowski MF, Winquist RA, Hansen AT. Fractures of the femoral neck in patients between the ages of twelve and forty-nine years. *J Bone Joint Surg*. 1984:66-A:837 846.
3. Swiontkowski MF. Intracapsular fractures of the hip. *J Bone Joint Surg Am*. 1994;76-A:129 138.
4. Upadhyay A, Jain P, Mishra P, et al. Delayed internal fixation of fractures of the neck of the femur in young adults. *J Bone Joint Surg (Br)*. 2004;86-B:1035 1040.
5. Bray TJ. Femoral Neck Fracture Fixation: Clinical Decision Making. *Clin Orthop Rela Res*. 1997;339:20 31.
6. Tooke MT, Favero KJ. Femoral neck fractures in skeletally mature patients, fifty years old or less. *J Bone Joint Surg*. 1985;67-A:1255 1260.
7. Mitchell, EJ. The technique: surgical approach and tactics for open reduction/internal fixation of a femoral neck fracture in a young patient. *Tech Ortho*. 2008;23:296 300.
8. Bertin KC, Röttinger H. Anterolateral mini-incision hip replacement surgery: a modified Watson-Jones approach. *Clin Orthop Rela Res*. 2004; 429:248 255.
9. Jacobs MA, Goytia RN, Bhargava T. Hip resurfacing through an anterolateral approach: surgical description and early review. *J Bone Joint Surg*. 2008;90-A:38 44.
10. Steffen R, O'Rourke K, Gill HS, et al. The anterolateral approach leads to less disruption of the femoral head-neck blood supply than the posterior approach during hip resurfacing. *J Bone Joint Surg (Br)*. 2007;89-B: 1293 1298.
11. Swiontkowski MF, Thorpe M, Seiler JG, et al. Operative management of displaced femoral head fractures: case-matched comparison of anterior versus posterior approaches for Pipkin I and Pipkin II fractures. *J Orthop Trauma*. 1992;6:437 442.
12. Light TR, Keggi KJ. Anterior approach to hip arthroplasty. *Clin Orthop Rela Res*. 1980:152:255 260.
13. Kennon RE, Keggi JM, Wetmore RS, et al. Total hip arthroplasty through a minimally invasive anterior surgical approach. *J Bone Joint Surg Am*. 2003;85-A:39 48.
14. Kennon R, Keggi J, Zatorski LE, et al. Anterior approach for total hip arthroplasty: Beyond the minimally invasive technique. *J Bone Joint Surg Am*. 2004;86-A:91 97.
15. Matta JM, Shahrdar C, Ferguson T. Single-incision anterior approach for total hip arthroplasty on an orthopaedic table. *Clin Orthop Rela Res*. 2005; 441:115 124.
16. Michael MC, Witschger P. MicroHip: a minimally invasive procedure for total hip replacement surgery using a modified Smith-Petersen approach. *Orthop Traumatol Rehabil*. 2007;9:46 51.
17. Matta JM, Ferguson TA. The anterior approach for hip replacement. *Orthopedics*. 2005;28:927 928.
18. Paillard P. Hip replacement by a minimal anterior approach. *Int Orthop*. 2007;31:S13 S15.
19. Smith-Petersen MN. A new supra-articular approach to the hip joint. *Am J Orthop Surg*. 1917;15:592 595.
20. Smith-Petersen MN. Approach to and exposure of the hip joint for mold arthroplasty. *J Bone Joint Surg*. 1949;31-A:40 46.
21. Molnar RB, Routt ML. Open reduction of intracapsular hip fractures using a modified Smith-Petersen surgical exposure. *J Orthop Trauma*. 2007;21:490 494.
22. Hoppenfeld S, deBoer P. The hip and acetabulum. In: Hurley R, Wolfberg E, eds. *Surgical Exposures in Orthopaedics: The Anatomic Approach*. 3rd ed. Philadelphia: Lippincott Williams & Wilkins, 2003:368 383.
23. Ganz R, Gill TJ, Gautier E, et al. Surgical dislocation of the adult hip: A technique with full access to femoral head and acetabulum without the risk of avascular necrosis. *J Bone Joint Surg (Br)*. 2001;83:1119 1124.
24. Gautier E, Ganz K, Krugel N, et al. Anatomy of the medial femoral circumflex artery and its surgical implications. *J Bone Joint Surg (Br)*. 2000;82:679 683.
25. Rasband WS. *ImageJ*. Bethesda, MD: US National Institutes of Health. Available at: http://rsb.info.nih.gov/ij/, 1997 2008. Accessed December 1, 2008.
26. Hussell JG, Mast JW, Mayo KA, et al. A comparison of different surgical approaches for the periacetabular osteotomy. *Clin Orthop Rela Res*. 1999; 363:64 72.
27. Olson, SA. Femoral neck fractures [PowerPoint slides]. Orthopaedic Trauma Association: Trauma & Fracture Care Residency Core Curriculum Lectures, Version II. Available at: http://www.ota.org/res slide/download. html. Accessed January 15, 2009.

 © 2010 Lippincott Williams & Wilkins

Copyright © Lippincott Williams & Wilkins. Unauthorized reproduction of this article is prohibited.